

# CXCL12 inhibition in MGMT unmethylated glioblastoma – Results of an early proof-of-concept assessment in the multicentric phase I/II GLORIA trial (NCT04121455)

Frank A. Giordano, Julian P. Layer, Sonia Leonardelli, Lea Friker, Clemens Seidel, Thomas Zeyen, Christina Schaub, Elena Sperk, Franziska Grau, Daniel Paech, Alexander Radbruch, Katharina Sahm, Sied Kebir, Peter Hamsch, Thorsten Pietsch, Martin Glas, Sotirios Bisdas, Michael Hölzel, Ulrich Herrlinger

Abstract #: CTNI-43

 [Frank.Giordano@ukbonn.de](mailto:Frank.Giordano@ukbonn.de)  
 [@FrankGiordanoJr](https://twitter.com/FrankGiordanoJr)



# Disclosures



**Research Grants:** Carl Zeiss Meditec AG, NOXXON Pharma AG, Elekta AB, GUERBET SA

**Personal Fees:** Carl Zeiss Meditec AG, Roche Pharma AG, NOXXON Pharma AG, Bristol-Myers Squibb, MSD Sharp and Dohme, Medac GmbH, GUERBET SA, AstraZeneca

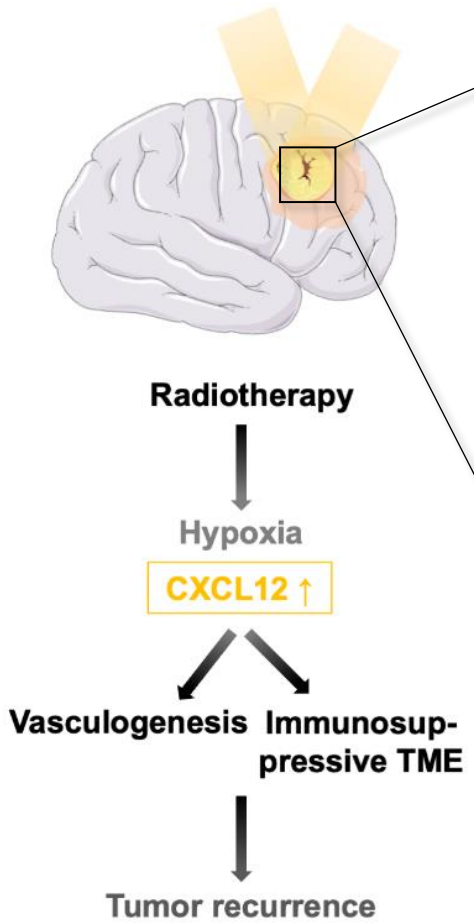
**Stocks:** Implacit GmbH, NOXXON Pharma AG

**Employee:** University Hospital Bonn, MVZ Venusberg GmbH

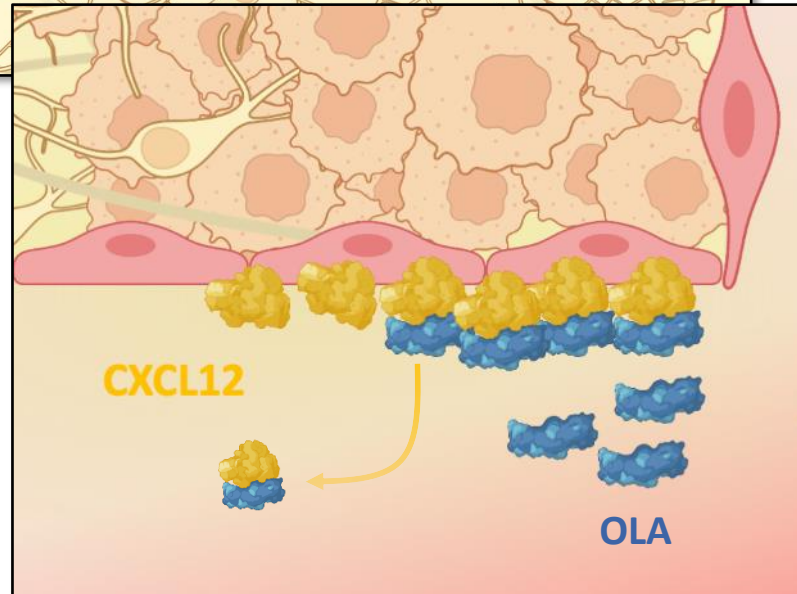
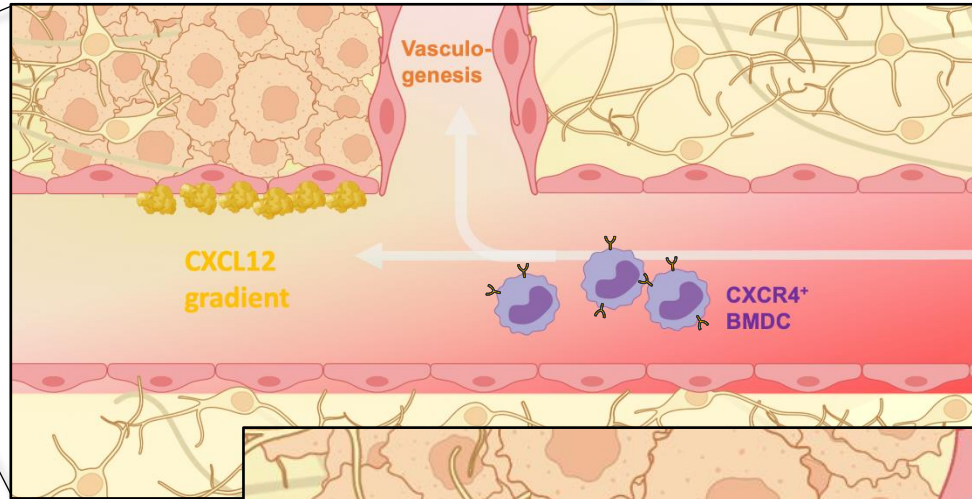
**Non-financial support:** Oncare GmbH, Opasca GmbH

The trial presented within this presentation is sponsored by NOXXON Pharma AG, Berlin, Germany. Statements given in this presentation may reflect personal opinions and experiences and do not necessarily reflect the opinions of NOXXON.

# Background and rationale



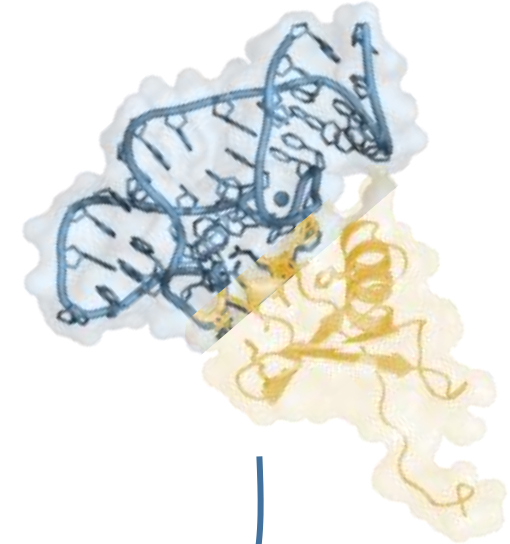
Ceradini, *Nat Med* 2004  
 Greenfield, *J Clin Invest.* 2010  
 Kioi, *J Clin Invest.* 2010  
 Liu, *Neuro Oncol.* 2014



CXCR4, C-X-C Motif Chemokine Receptor 4 (receptor for CXCL12)  
 BMDC, bone marrow derived cells  
 TME, tumor microenvironment

## Olaptesed pegol (OLA, NOX-A12)

RNA Spiegelmer (L-stereoisomer)



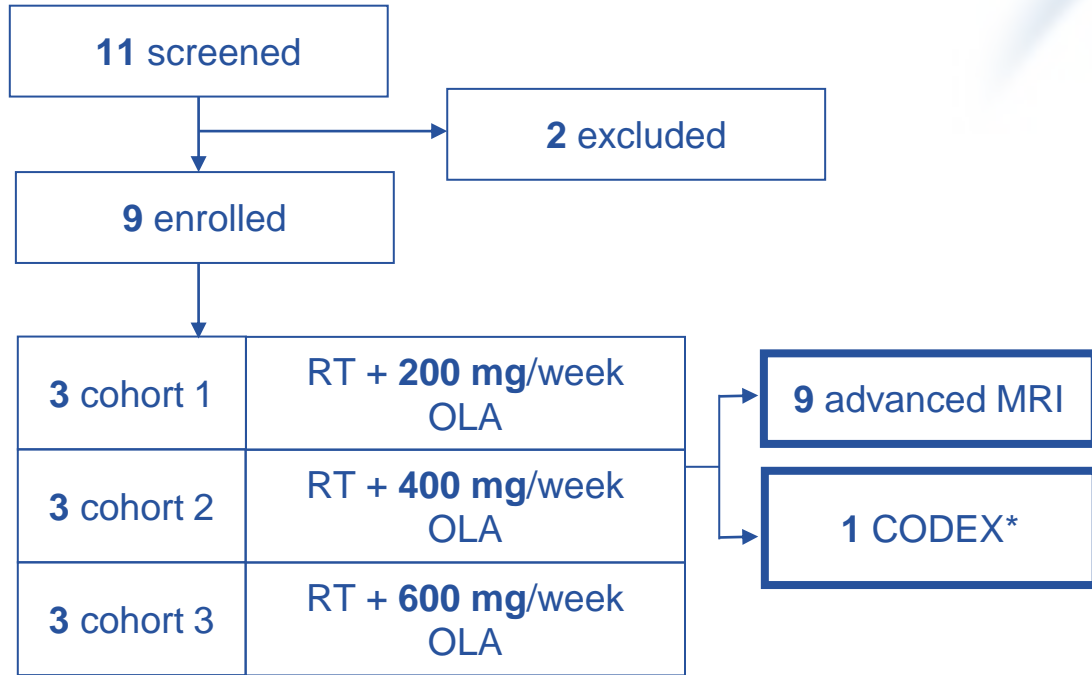
binds & neutralizes  
**CXCL12**



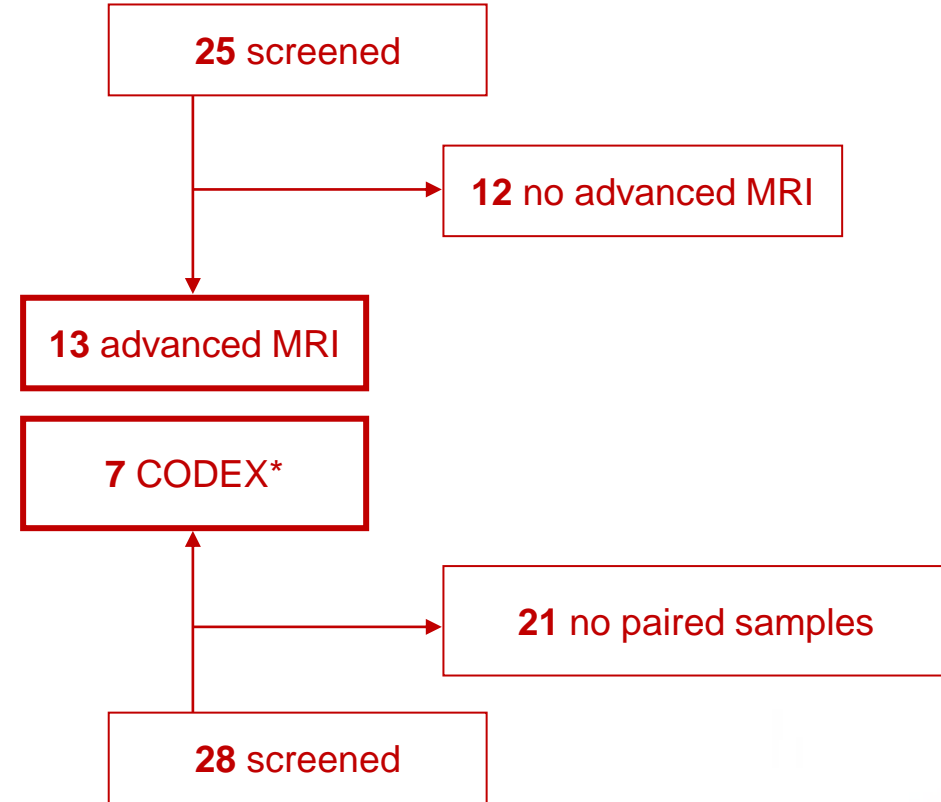
# CONSORT of GLORIA and controls



## GLORIA



## Matched Imaging Control Cohort\*\*



## CODEX Control Cohort

\* Only performed for paired samples from 1<sup>st</sup> and 2<sup>nd</sup> surgery.

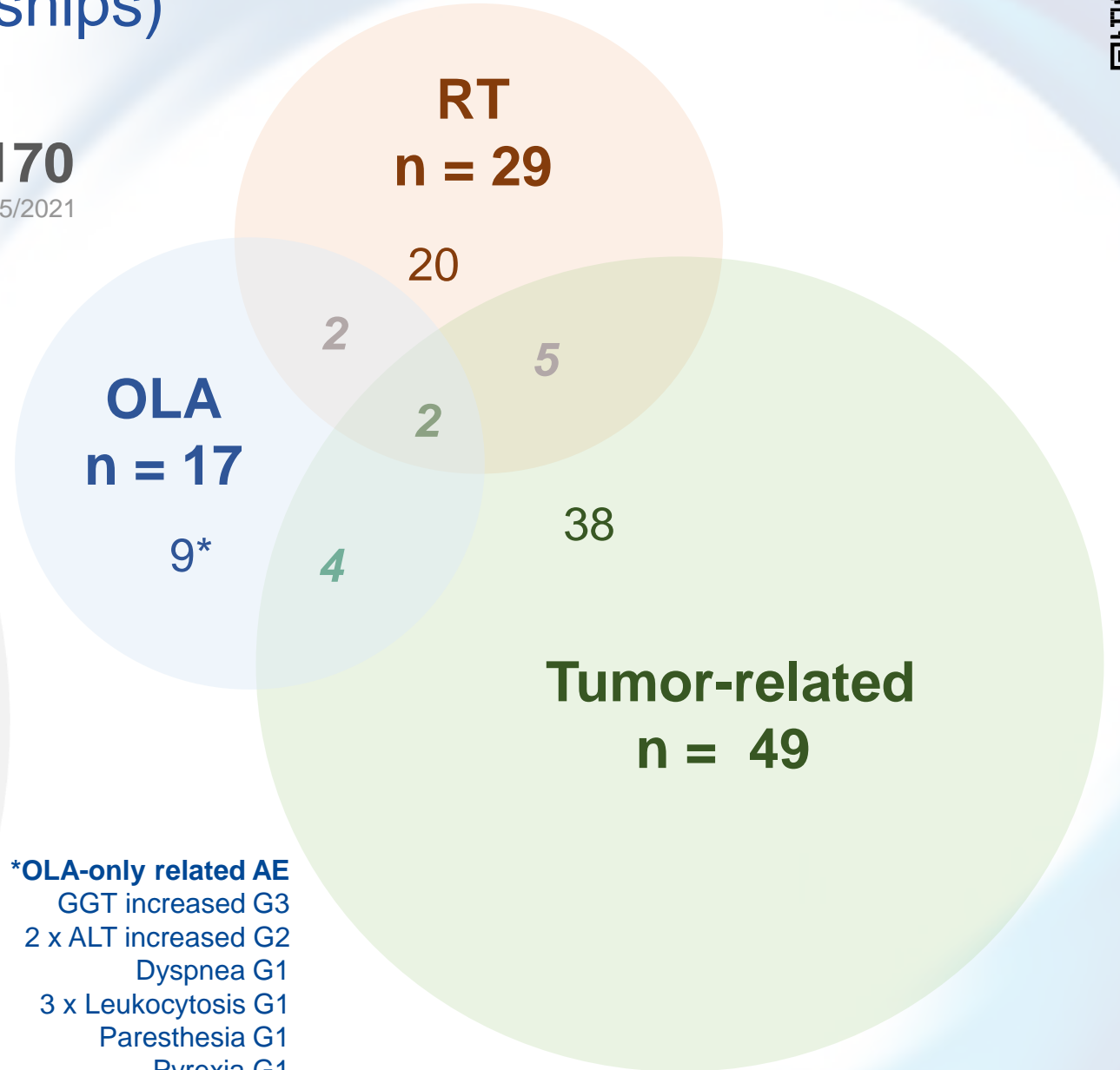
\*\* Matched per MGMT promoter methylation status and extent of resection. Patients in the control cohort needed to have at least 3 consecutive scans.

# Primary EP: Safety (AE relationships)



**All: n=170**  
cut-off date: 10/15/2021

**No relation**  
**n = 75**

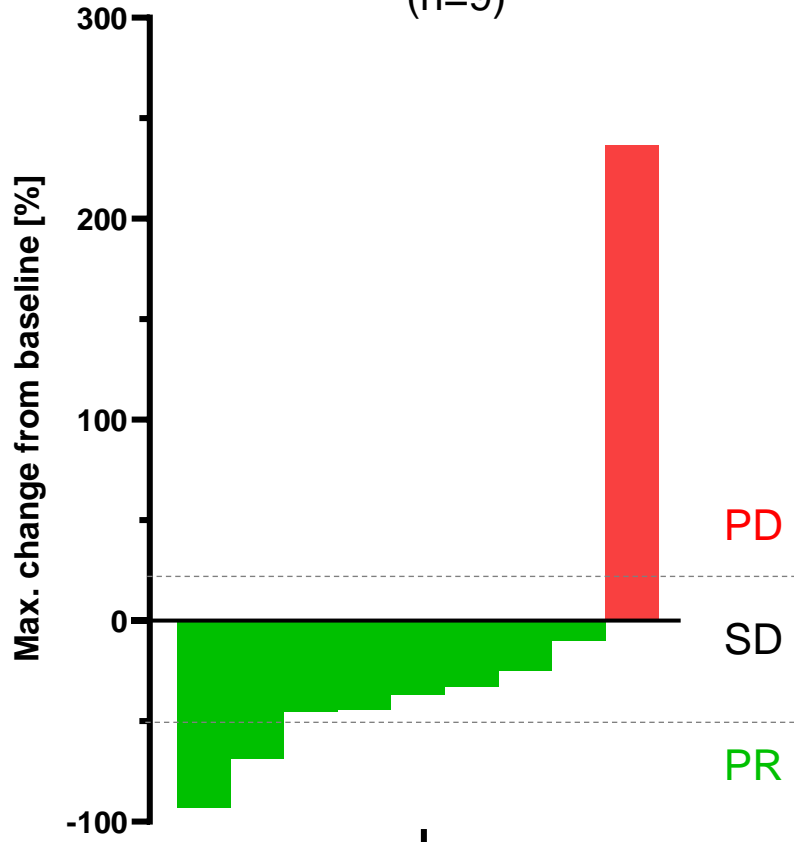


**\*OLA-only related AE**  
GGT increased G3  
2 x ALT increased G2  
Dyspnea G1  
3 x Leukocytosis G1  
Paresthesia G1  
Pyrexia G1

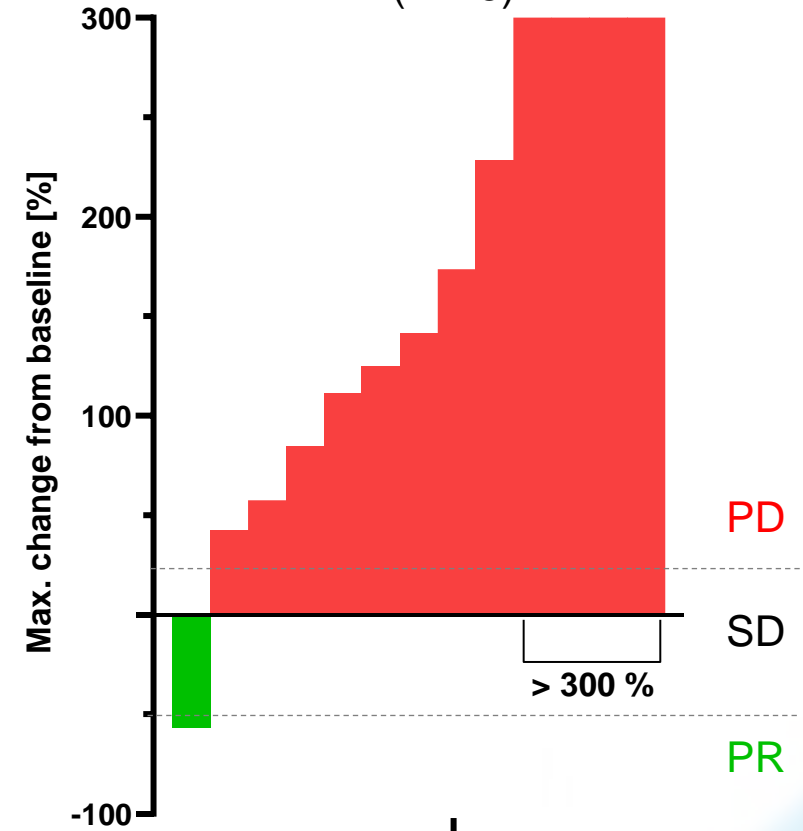
# Best response under OLA (volume of T1 enhancing lesions)



## $V_{T1}$ GLORIA Independent Central Review (n=9)



## $V_{T1}$ Matched Imaging Control Cohort (n=13)



p=0.0026

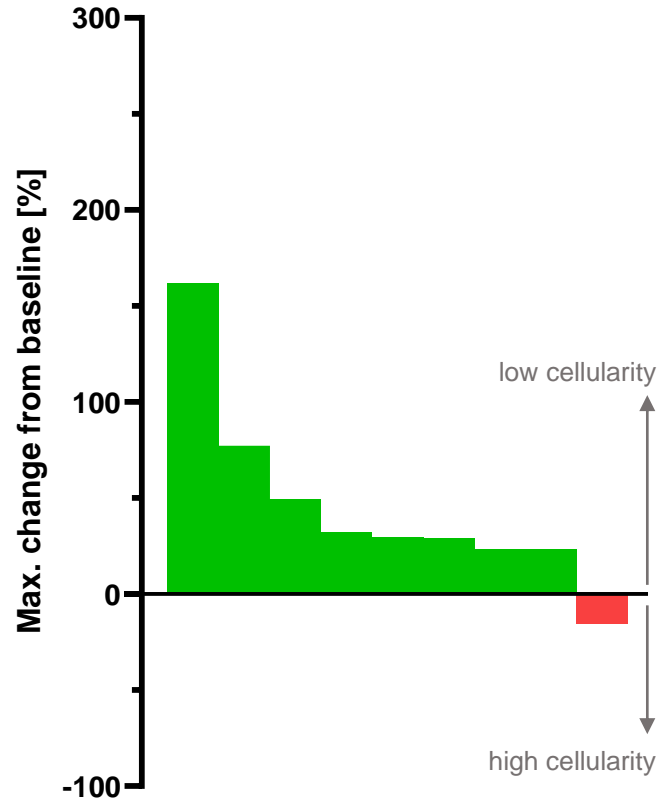
Non-parametric Mann Whitney U test

# Best response in cellularity and tumor perfusion under OLA



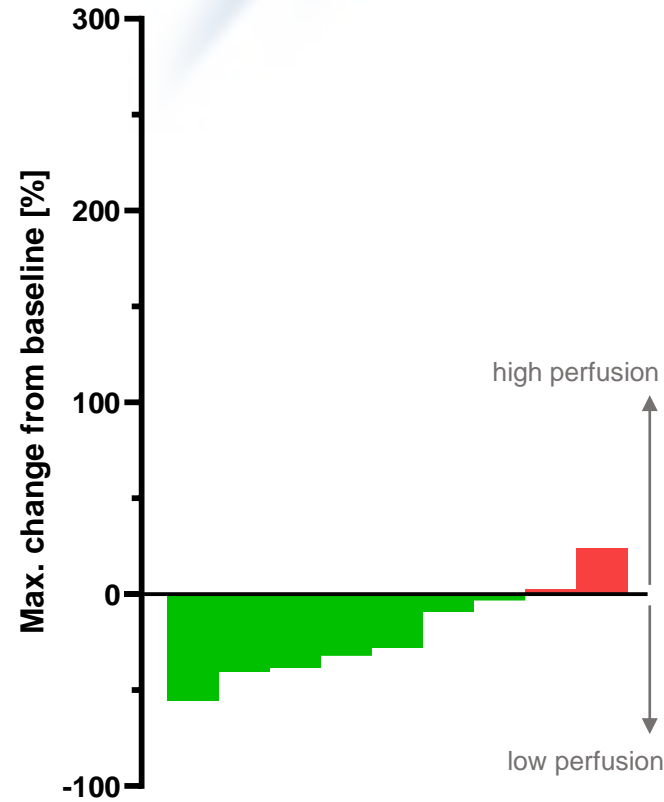
## ADC mean

(Independent Central Review, n=9)



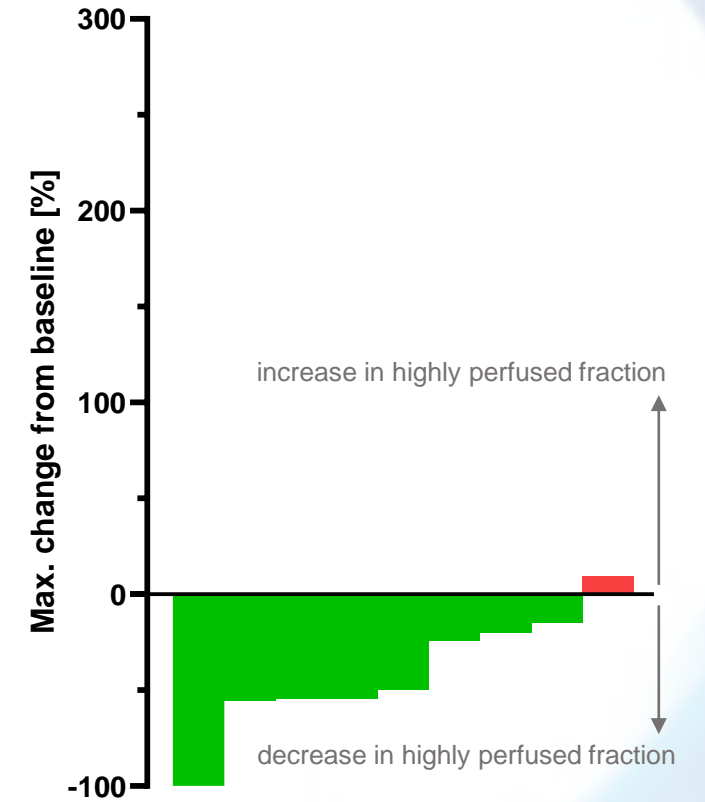
## rCBV mean

(Independent Central Review, n=9)



## FTB<sup>high</sup>

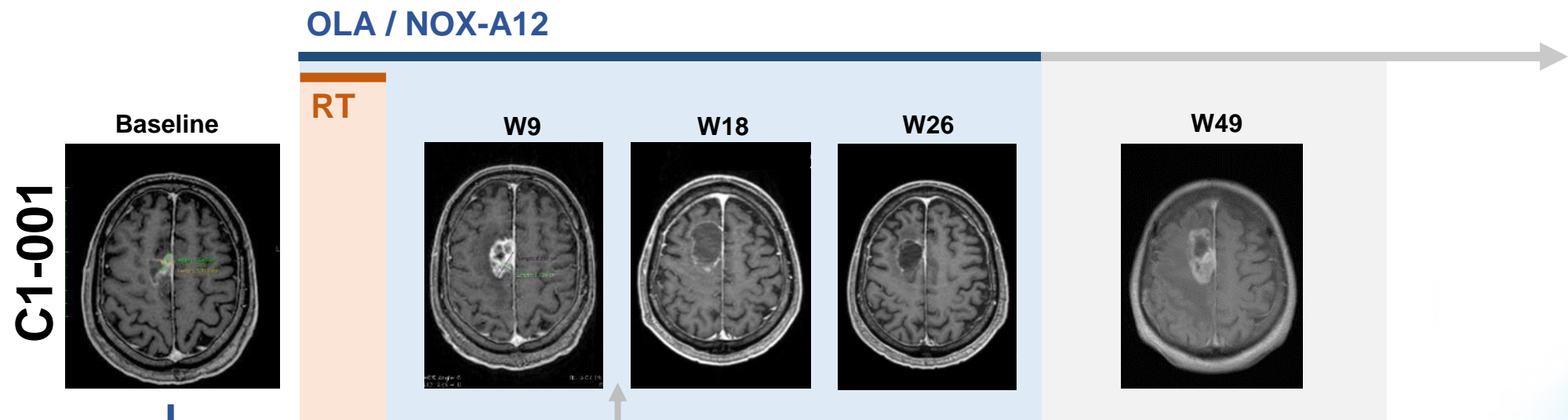
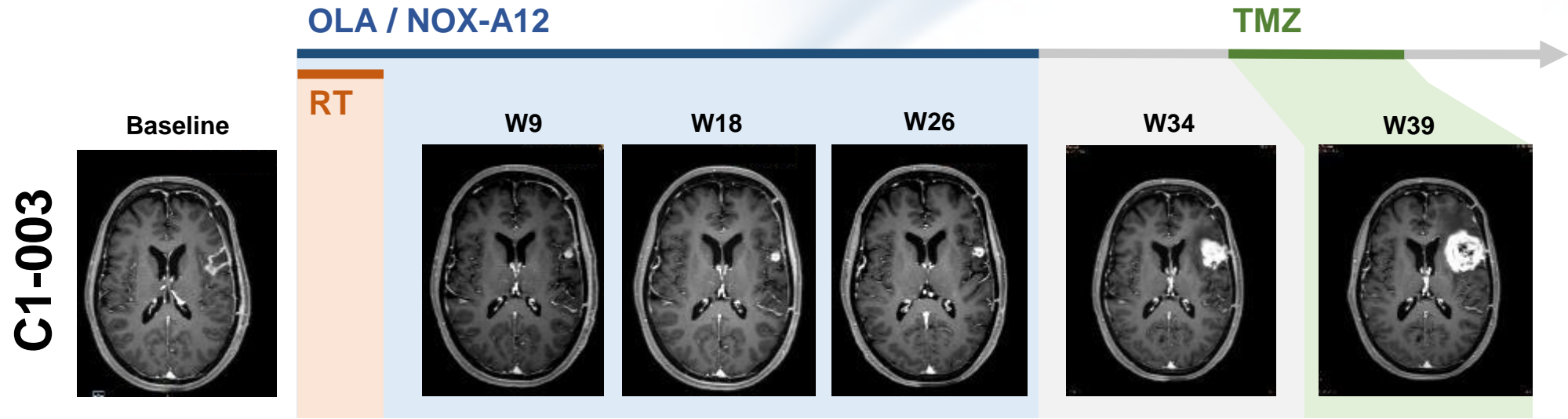
(Independent Central Review, n=9)



ADC, apparent diffusion coefficient (derived parameter from DWI sequences)  
rCBV, standardized relative cerebral blood volume (derived parameter from DSC sequences)  
FTB<sup>high</sup>, fractional tumor burden with rCBV > 1.75



# Exemplary response to RT/OLA



re-surgery for suspected PD  
path report: Ki67<5%

→

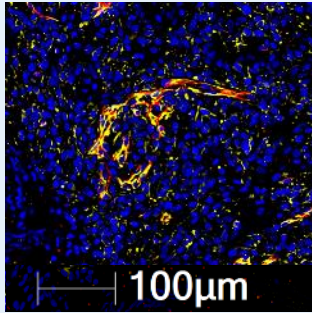
**CODEX**

# CODEX: RT/OLA reduces CXCL12 levels in the tumor endothelium

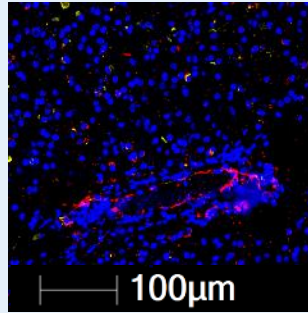


**GLORIA**  
C1-001

Baseline

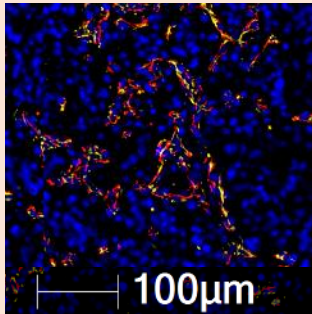


Post RT / under OLA

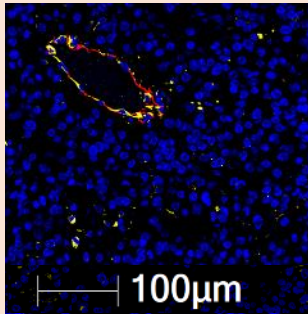


DAPI  
CD31  
CXCL12

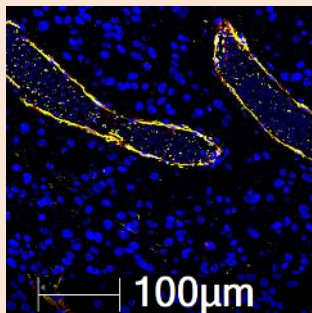
Baseline



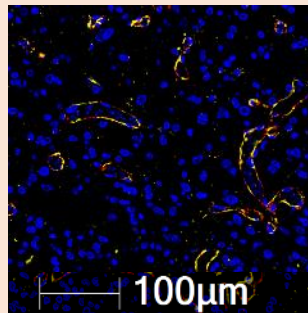
Post RT/TMZ



Baseline



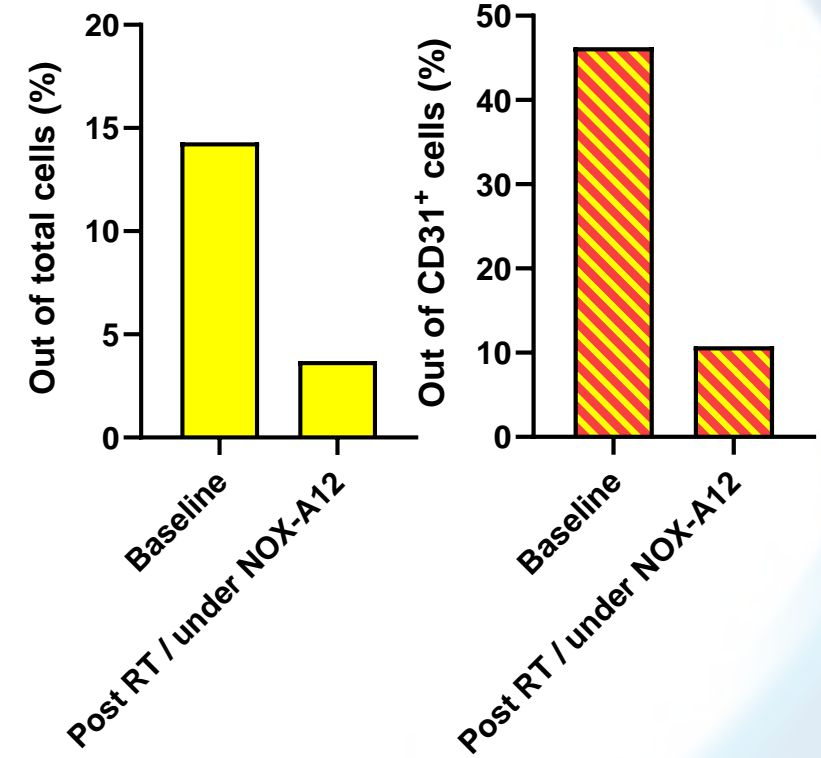
Post RT/TMZ/NIVO



**References**

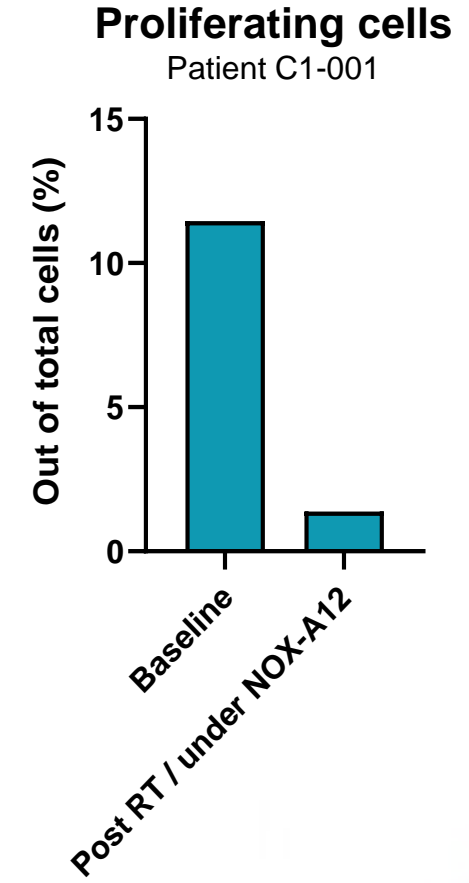
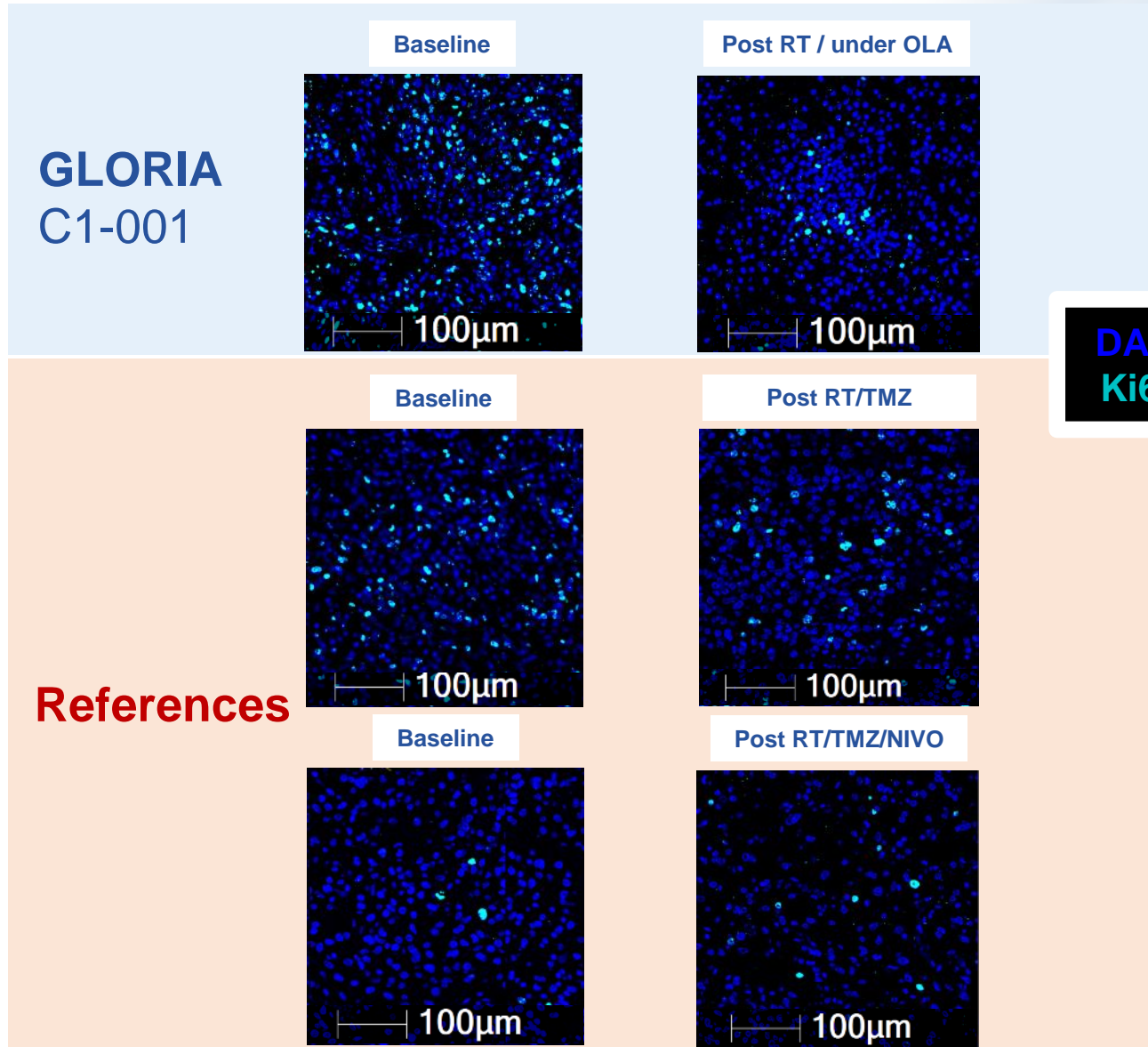
**CXCL12+ cells**

Patient C1-001



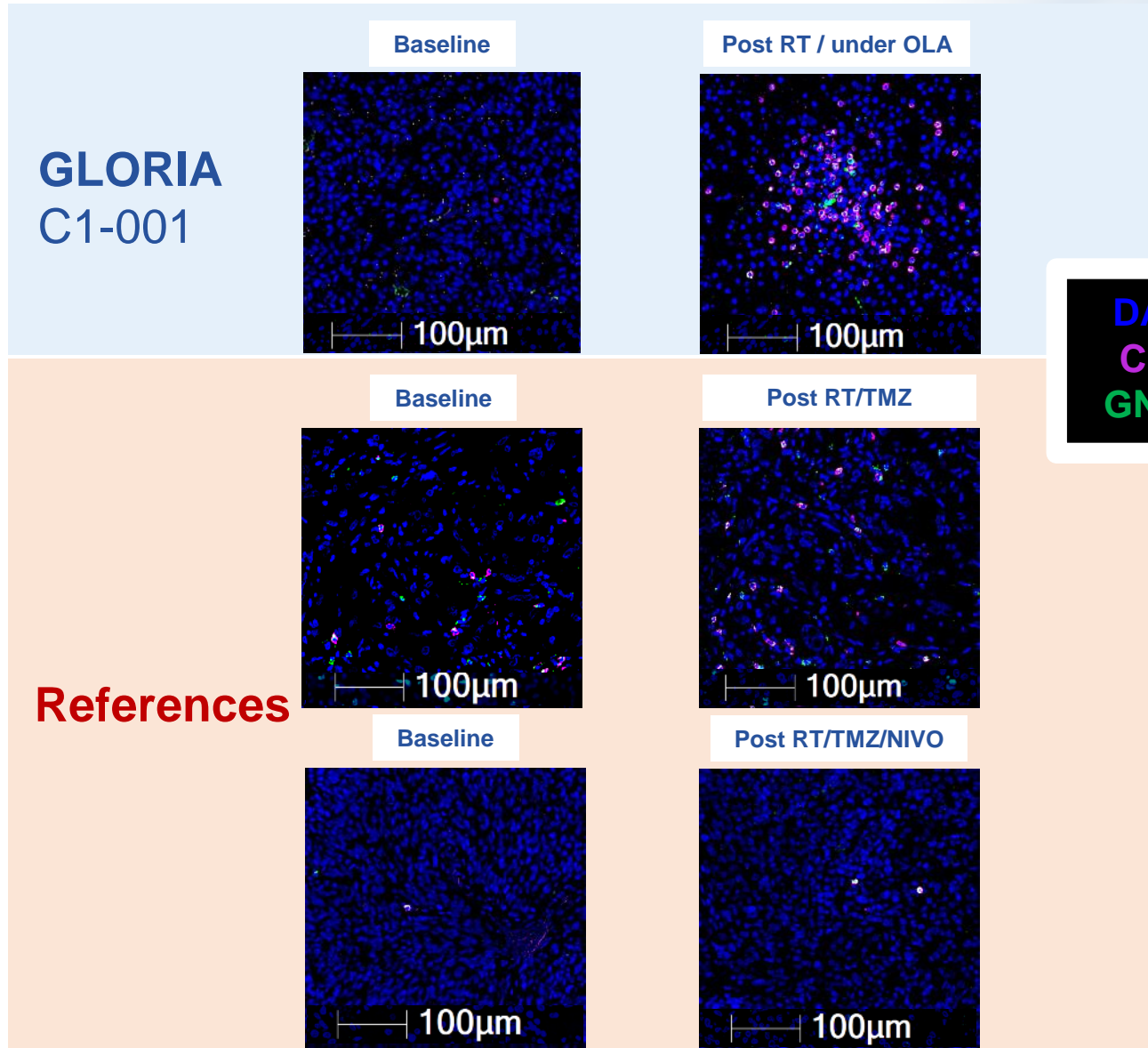
Images show areas of pathologist-confirmed tumor tissue

# CODEX: RT/OLA reduces tumor cell proliferation



Images show areas of pathologist-confirmed tumor tissue

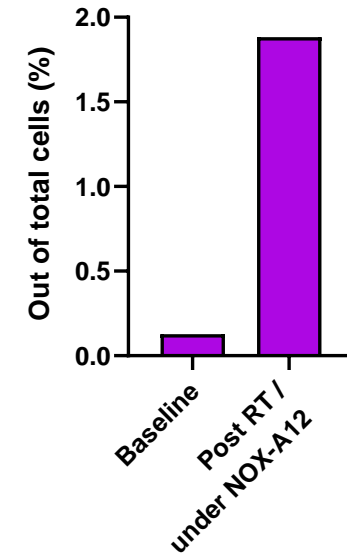
# CODEX: Cytotoxic T cell infiltration and activation



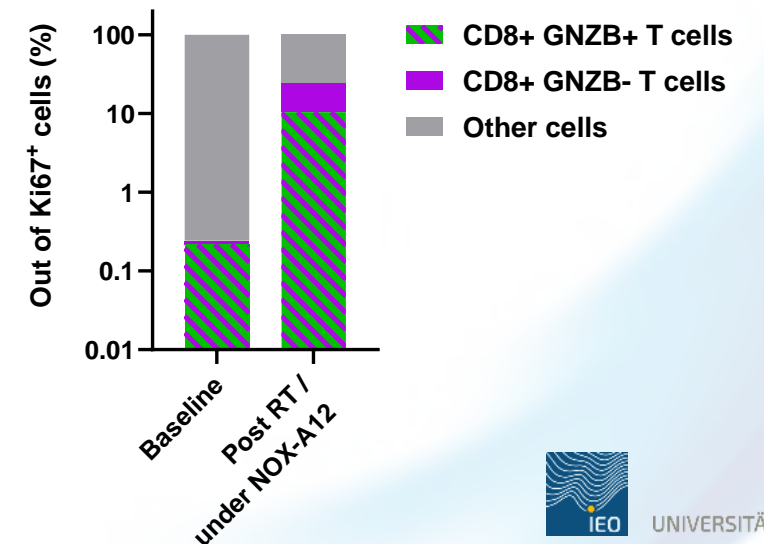
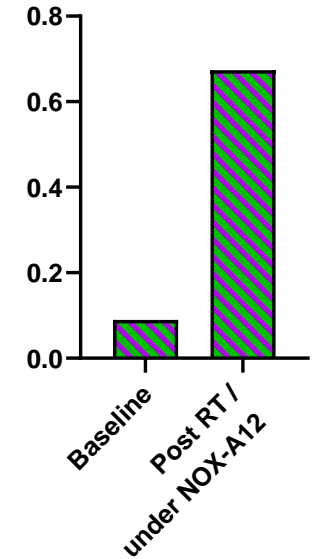
DAPI  
CD8  
GNZB

Images show areas of pathologist-confirmed tumor tissue

**CD8+**  
Patient C1-001



**GNZB+ CD8+**  
Patient C1-001

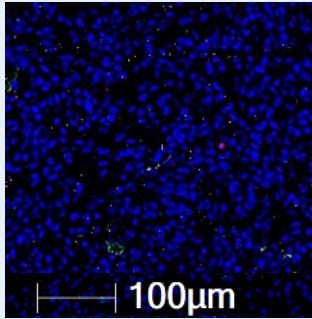


# CODEX: Cytotoxic T cell infiltration and activation

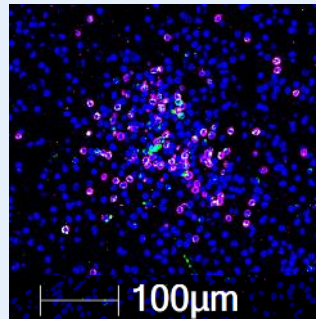


GLORIA  
C1-001

Baseline

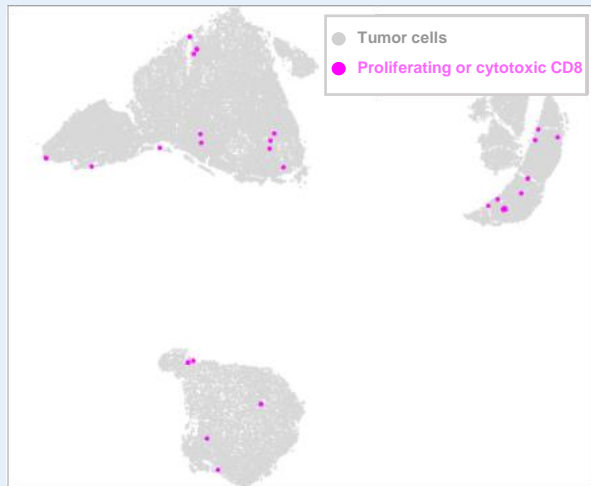


Post RT / under OLA

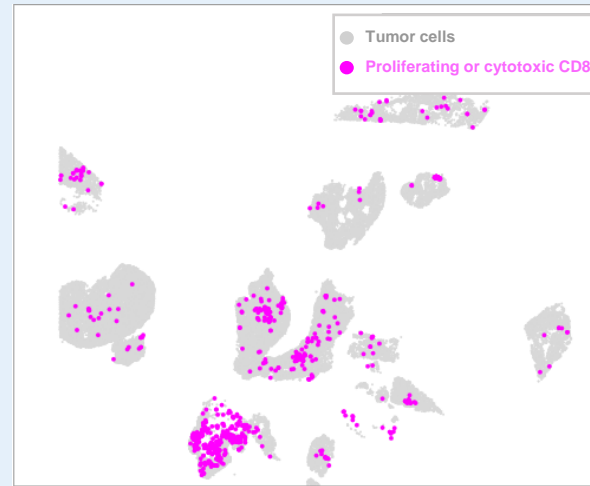


## Whole slide spatial Analysis

Baseline

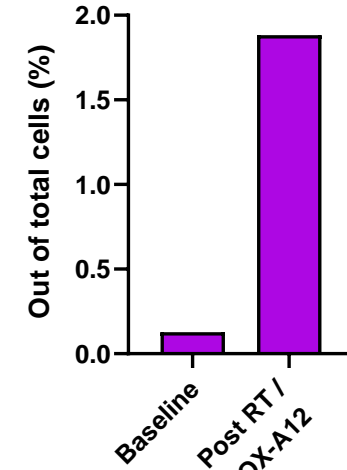


Post RT / under OLA

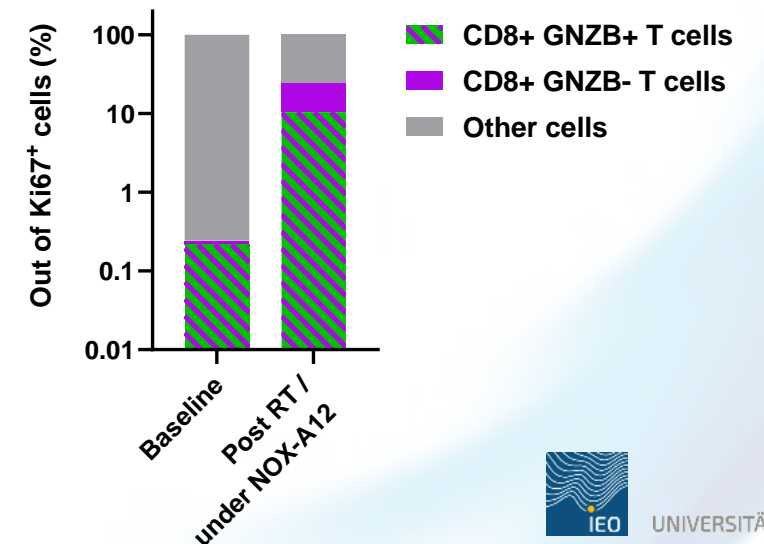
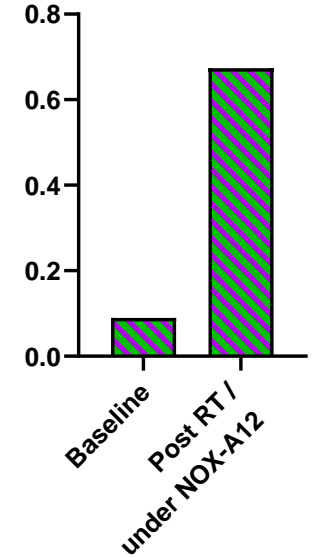


Images show areas of pathologist-confirmed tumor tissue

**CD8+**  
Patient C1-001



**GNZB+ CD8+**  
Patient C1-001



# Conclusions – GLORIA Study



- **Combined RT + OLA (NOX-A12) treatment is feasible and safe**
- **Initial promising efficacy signals**
  - 8 out of 9 patients showed a response as per volume of T1-contrast (2 x PR)
  - reduced cellularity in 8 out of 9 patients
  - reduced perfusion 7 out of 9 patients
- **Tissue analysis (re-surgery under OLA) confirms mode(s) of action:**
  - CD31/CXCL12 co-localization is abrogated
  - Strong reduction in tumor cell proliferation
  - CD8+ T cell count increases by 15-fold
  - *De-novo* clusters of proliferating and cytotoxic CD8+ T cells
- **Follow-up ongoing, expansion cohorts planned**

# Acknowledgements



## **UKB Radiation Oncology**

Julian P. Layer  
Katja Klever

## **UKB Exp. Oncology**

Michael Hölzel  
Sonia Leonardelli  
Roberta Turiello

## **UKB Neuro-Oncology**

Ulrich Herrlinger  
Christiane Landwehr  
Thomas Zeyen  
Christina Schaub  
Mirco Muscheid

## **UKB Neuropathology**

Thorsten Pietsch  
Lea Friker

## **UC London**

Sotirios Bisdas

## **UKB Neuroradiology**

Alexander Radbruch  
Daniel Paech  
Franziska Grau

## **Uni Heidelberg**

### **UH Mannheim**

Elena Sperk  
Katharina Sahm  
Michael Platten

### **UH Leipzig**

Clemens Seidel  
Peter Hambsch  
Nadja Talhi

### **UH Essen**

Martin Glas  
Sied Kebir  
Sarina Agkatsev



**ImmunoSensation<sup>2</sup>**  
the immune sensory system Bonn cluster of excellence



@ Frank.Giordano@ukbonn.de